

Comparison of Hoof Bath Solutions for the Prevention and Control of Digital Dermatitis in Dairy Cows

D. Döpfer^{1*}, U. Desranleau Dandurand², A. Desrochers³, A. Letellier², S. Quessy², A. Bourgeois⁴, C. Frenette Dussault⁵ & M. Allard²

¹UW-Madison, USA, ²Laboratoire M2, Canada, ³Université de Montréal, Canada, ⁴Clinique vétérinaire de Sherbrooke, Canada, ⁵Université de Sherbrooke, Canada *dopferd@vetmed.wisc.edu

Introduction

- Digital dermatitis (DD) is a widespread and costly disease in dairy herds and hoof baths are commonly used to prevent DD.
- Many chemicals (CuSO₄, formalin) used in footbaths can be hazardous to human health and the environment.
- A solution comprising thymol, **THYMOX**, is a safer biocide with antimicrobial activity.



Thymol mode of action: Induces instability in microorganisms' membrane, causing cell content leakage and death.

- In vitro*: **THYMOX** inhibited the growth and killed treponemes isolated from DD (Table 1)

Table 1. *In vitro* efficacy on *Treponema*


	THYMOX	CuSO ₄
Working concentration in hoof baths	1%	5%
MIC at Minimal exposure time with 20% manure	0.004 %	0.019 %

Hypothesis: **THYMOX** will be effective in controlling DD in endemically affected cows housed in free stall barns.

Methods

1. Compare THYMOX and CuSO₄ in different farms


Hoof baths 3 X / week, Weeks 0 to 12



2. Compare THYMOX and CuSO₄ in the same farm

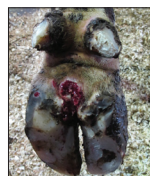Hoof baths 3 X / week, Weeks 12 to 24

Farm 1 switched to THYMOX at Week 12: limit farm variability



Hooves evaluated for lesions¹ at weeks 0, 6, 12, 18 and 24

- M0:** Healthy epidermis
- M1:** DD lesion, early stage
- M2:** Active lesion, ulcerative stage
- M3:** Healing lesion, transitory stage
- M4:** Chronic lesion, reservoir for new active lesions



M1 and M2

Topical application of tetracycline and bandage

Results

The number of transitions between the M-stages were counted and transformed into a probability matrix able to predict the relative frequencies of the M-stages after prolonged periods of time (Figure 1).

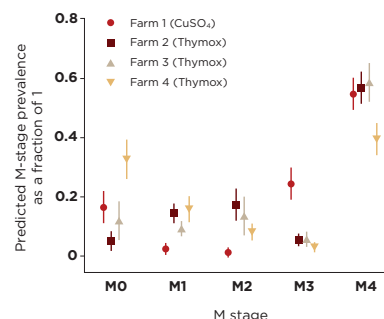


Figure 1. Average predicted prevalence after a "long period of time" and their 95% confidence intervals per farm.

1. Performance of THYMOX and CuSO₄ in different farms. Significant differences:

- Less M1 and M2 lesions predicted in Farm 1 (CuSO₄)
- More healing M3 lesions predicted in Farm 1 (CuSO₄)
- Less chronic M4 lesions predicted in Farm 4 (THYMOX)
- More healthy hooves M0 predicted in Farm 4 (THYMOX)

Differences due to variability between farms?

2. Performance of THYMOX and CuSO₄ in the same farm (Figure 2).

Weeks 0 - 12: CuSO₄ Hoof baths:

- Decrease of M1-M2 lesions
- Increase of chronic M4 lesions

Weeks 12 - 24: THYMOX Hoof baths:

- Low levels of M1-M2 maintained
- Decrease of chronic M4 lesions
- Increase of healthy hooves (M0)

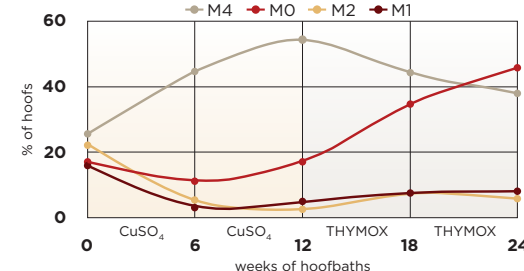


Figure 2. Percentage of hooves for the different M-stages after weeks of hoof baths of CuSO₄ (1-12) and THYMOX (12-24) in Farm 1.

Discussion

- Chronic lesions: Long-term reservoirs of DD active lesions.
- Increased chronic lesions: problem under the impact of risk factors such as bad hygiene.
- THYMOX associated with the prediction of less chronic lesions
- THYMOX associated with the prediction of more healthy hooves

It is strongly advised to take these long-term effects into account when adopting new hoof bath agents. Early detection and prompt topical treatment of active M2 lesions are essential for the success of a hoof bathing strategy.

¹ Berry SL, Read DH, Famula TR, Mongini A and Döpfer D 2012 Long-term observations on the dynamics of bovine digital dermatitis lesions on a California dairy after topical treatment with lincomycin HCl. Vet J. 193:654-658.